

# ***Spondias mombin* (HOG PLUM) AQUEOUS EXTRACT COULD POSSESS HEPATOCYTIC POTENTIALS AFTER INGESTION OF MONOSODIUM GLUTAMATE (MSG)**

## **ABSTRACT**

Intake of chemicals like monosodium glutamate (MSG) enhances the prevalence of leiomyoma. Leiomyoma has no known cure but *Spondias mombin* leaves have been in use, locally, in its management among Igbos of southeastern Nigeria. This work investigated the effect of *S. mombin* extract on hepatocytes after ingesting MSG. Twenty-one rats used in this study were divided into three groups of seven rats each and acclimatized. Two groups had fibroid after daily ingestion of 750mg/kg body weight of MSG for 28 days. Negative control had no fibroid. Positive control had fibroid and remained untreated. Group III, with fibroid, were continuously ingested with same dose of MSG for the next 28 days in addition to daily oral treatment with 250mg/kg body weight of aqueous extract of *Spondias mombin*. Histological examinations of rat's hepatocytes were performed on 2<sup>nd</sup> and 4<sup>th</sup> weeks, respectively, using two rats from each group for the next 28 days. Results indicated that the aqueous extract of *S. mombin* did not preserve rat's hepatocytes. Ingestion of *S. mombin* aqueous extract is deleterious to hepatocytes and could lead to other liver diseases. Results further indicated that continuous ingestion of MSG is destructive to hepatocytes. Care should be applied while ingesting aqueous extract of *S. mombin* either as a prophylaxis or as a chemotherapeutic agent. Result of this study had shown that oral intake of MSG has the potential of inducing uterine leiomyoma in experimental albino Wistar rats.

Keywords: Leiomyoma, fibroid, monosodium glutamate (MSG), *Spondias mombin*, hepatocytes.

## **INTRODUCTION**

Civilization has made the use of chemicals part of human life. These chemicals, mostly synthetic products, have found entry into human diets. They are used as food seasoning agents and include monosodium glutamate (MSG) (Sharma et al. 2013). Monosodium glutamate is an endocrine disruptor (WHO/UNEP, 2013) which is toxic to humans and experimental animals (Egbuonu et al. 2010). Once ingested, MSG initiates the excessive generation of reactive oxygen species (ROS) (Sharma, 2015). MSG is a bleaching agent used in laundry for stain removal (Olugbenga et al. 2014). And I have reported the use of MSG to induce leiomyoma in laboratory female Wistar rats (Eze-Steven, 2019). The incidence of fibroid, in Nigeria, is high among reproductive-aged women and it ranges from 17.9 – 26% compared to 5 – 11% reported in Europe and United States (Ekine et al. 2015).

The choice of alternative medicine in treatment of diseases is on the increase with *Spondias mombin* Linn used in treating postpartum infections (Uchendu and Isek, 2008). However, the effect of this plant on hepatocytes has not been investigated, hence this study. The objective of this study is to investigate the effects of *Spondias mombin* leaves on hepatocytes of female Wistar rats ingested with monosodium glutamate.

## **Materials and Methods**

This study was carried out in the Industrial Biochemistry Research Laboratory at the Biochemistry Department of Enugu State University of Science and Technology (ESUT), Agbani, Enugu State and Histopathology Laboratory of ESUT Teaching Hospital, Enugu, Enugu State, Nigeria.

Young fresh leaves of Hog plum (*Spondias mombin*) harvested from ESUT surroundings around 4.00pm were used. Leaves were identified by Professor J. C. Okafor, a Taxonomist with the Applied Biology and Biotechnology Department, Enugu State University of Science and Technology, Enugu State.

Soxhlet method described by Redfern et al. (2014) was used in preparing the aqueous extract.

### **Animal Studies**

Apparently healthy adult female Wistar albino rats of about 6 to 8 weeks old with average weight of 150 to 250g were the experimental animals used for this research study. Rats were confirmed as adults following the method described by Lenschow et al. (2017). All the rats were obtained from Faculty of Veterinary Sciences, University of Nigeria, Nsukka (UNN).

### **Preparation of Monosodium Glutamate (MSG) Solution**

The solutions of the MSG given to all animals were prepared following the dissolution of a calculated volume of MSG in a warm water (MSG is sparingly soluble in cold water/water at room temperature but readily soluble in hot water).

### **Experimental Design**

#### **Leiomyoma induction and treatment**

Twenty-one (21) adult female albino Wistar rats were used in this study. Animals were acclimatized for two (2) weeks and divided into three (3) groups of seven (7) rats each. All animals were fed orally according to the methods described by Wheatley, (2002).

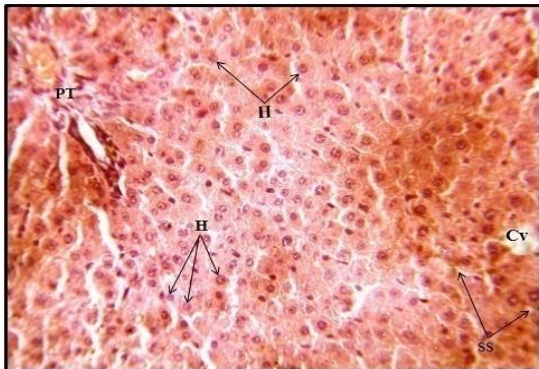
The negative control group was fed on poultry growers' mash and water only. The positive control group received feed, water and 750mg/kgbw of MSG daily for twenty-eight (28) days. Group III rats received feed, water and 750mg/kgbw of MSG daily for twenty-eight (28) days and later treated with 250mg/kgbw of aqueous extract of hog plum daily while receiving food, water and 750mg/kgbw of MSG for another twenty-eight (28) days.

Leiomyoma was induced in rats in the positive control and Group III following the initial administration of 750mg/kgbw of MSG daily for twenty-eight (28) days. Group III rats continued to receive MSG with the *Spondias mombin* extract in the second twenty-eight (28) days as specified above according to the method described by Cheng et al. (2011).

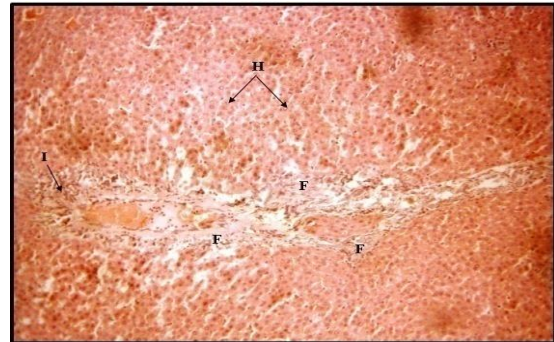
Histopathology procedures carried out on rats' hepatocytes were according to the method described by Slaoui and Fiette, (2011).

## Results and Discussion

Photomicrographs of tissues of negative control female albino Wistar rat compared with the positive control.

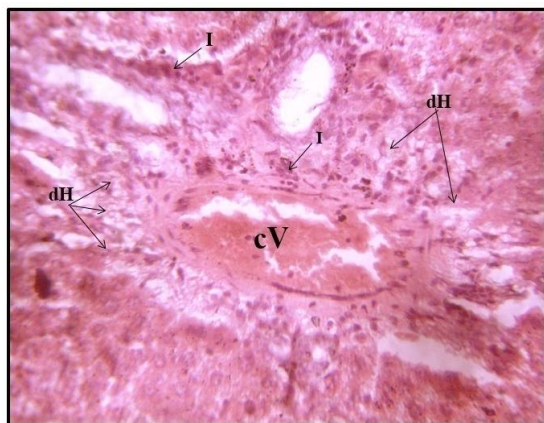

**Plate 1:** Liver section photomicrograph of Negative Control rat showing normal histoarchitecture of the hepatic tissue. The central vein (Cv), hepatocytes (H), portal tract (PT) and radiating sinusoidal spaces (SS) appear normal. (Stain: H&E; Mag: - x400)

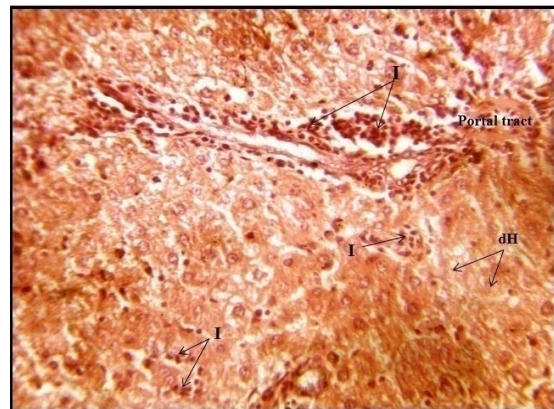


**Plate 2:** Liver section photomicrograph from Positive Control rats following MSG intoxication and not treated with the extract. There is evidence of cellular infiltration (I), tissue degeneration and septal fibrosis (F). However, most hepatocytes (H) within the hepatic lobule are normal. (Stain: H&E; Mag: - x100)

Photomicrographs of tissues of Group III female albino Wistar rats treated with water extract of *Spondias mombin* leaves.



**Plate 3:** Liver section photomicrograph of Group III rat treated with 250mg/kgbw of *Spondias mombin* for two weeks following MSG intoxication and showing congested vessel (cV), degenerating hepatocytes (dH) and inflammatory cellular infiltration (I). (Stain: H&E; Mag: x400)



**Plate 4:** Liver section photomicrograph of Group III rat treated with 250mg/kgbw of *Spondias mombin* water extract for four weeks following MSG intoxication showing degenerating hepatocytes (dH) and inflammatory cellular infiltration (I). (Stain: H&E; Mag: - x400)

The photomicrograph of the liver section of Negative Control rat show normal histoarchitecture of the hepatic tissue as shown in Plate 1.

Liver section of the Positive Control rat shows evidence of cellular infiltration and tissue degeneration (Plate 2) compared to Negative Control rat (Plate 1). The evidence of tissue degeneration as seen in Plate 2 is an indication of the oxidative powers of monosodium glutamate (MSG) ingestion. The liver, which is the major site of drug metabolism, was destroyed by the ingested monosodium glutamate.

Also, the rat's hepatocytes at two weeks of treatment gave evidence of degeneration (Plate 3) and same occurred at the fourth weeks of continuous treatment (Plate 4).

The effective dose (ED) of MSG in rats has been reported as 750mg/kgbw by Eze-Steven et al. (2019). At this dose, the ingestion of MSG yielded hepatotoxic and nephrodestructive damages. This could be due to its oxidizing effect on organs and tissues like the liver, which is the major cite of drug detoxifications. Monosodium glutamate ingestion has also been reported to cause degeneration of kidney cells and uterine walls (Eze-Steven et al. 2019) arising from its oxidative properties. This oxidative damage supports findings indicating the hepatotoxic effects of MSG (Kazmi et al. 2017).

There was haemorrhage and cellular infiltration in week 2 of MSG ingestion with *Spondias mombin* treatment and same occurred in week 4. Therefore, continuous intake of *S. mombin* aqueous extract did not preserve the hepatocytes as compared to its effect on kidney and endometrial cells of rats following the ingestion of MSG as reported by Eze-Steven (2019). Aqueous extract of *S. mombin* leaves indicated no potency in preserving the hepatocytes of laboratory test animals from the oxidative damage of MSG. This is an indication that the intake of *S. mombin* could not preserve the integrity of the rats' hepatocytes. *Spondias mombin* aqueous extract offered protection to endometrial cells induced with leiomyoma (Eze-Steven, 2019 and Eze-Steven et al. 2019) hence its use in treating postpartum infections (Uchendu and Isek, 2008). However, continuous use of this extract destroys hepatocytes. In conclusion, aqueous extract of *Spondias mombin* should be ingested with caution to avoid the oxidative destruction it exerts on hepatocytes.

## REFERENCES

- Cheng HG, Lan Z, Cui OC, Lang JH, Li B. (2011). Estrogen-induced rat model of uterine leiomyoma. *Acta Academiae Medicinae Sinicae*. 33(4): 408 – 411.
- Egbonu ACC, Ejikeme PM, Obasi LN. (2010). Influence of sub-chronic oral exposure to high monosodium glutamate on some serum markers of the renal functions in male Wistar rats. *African Journal of Biochemistry Research*. 4(9): 225 – 228.
- Eze-Steven PE. (2019). Histopathological investigations of *Curcuma longa* (Turmeric) and *Zingiber officinale* (Ginger) on rats with monosodium glutamate-induced leiomyoma. *Journal of Experimental Research*. 7(1): 9 – 15.
- Eze-Steven PE, Udedi SC, Ude CM. (2019). Effects of *Spondias mobin* and *Aspilia africana* aqueous extracts on rats with monosodium glutamate-induced leiomyoma. *Cross Current International Journal of Medical and Biosciences*. 1(1): 26 – 32.

- Ekine AA, Lawani LO, Iyoke CA, Jeremiah I, Ibrahim IA. (2015). Review of the clinical presentation of uterine fibroid and the effect of therapeutic intervention on fertility. *American Journal of Clinical Medicine Research*. 3(1): 9 – 13.
- Kazmi Z, Fatima I, Perveen S, Malik, SS. (2017). Monosodium glutamate: Review on clinical reports. *International Journal of Food Properties*. 20(S2): S1807 – S1815.
- Lenschow C, Sigl-Glockner J. Brecht, M. (2017). Development of rat female genital cortex and control of female puberty by sexual touch. *Public Library of Science Biology*. 15(9): 1 – 22.
- Olugbenga OO, Bukola OA, Odupitan BS. Emmanuel OA. (2014). Modulating effects of *Allium sativum* (garlic) extract in monosodium glutamate (Ajinomoto) induced injuries in rats. *Medicinal plants*. 6(1): 13 – 17.
- Redfern J, Kinninmonth M, Burdass D, Verran J. (2014). Using Soxhlet ethanol extraction to produce and test plant material (essential oils) for their antimicrobial properties. *Journal of Microbiology and Biology Education*. 15(1): 45 – 46.
- Sharma A. (2015). Monosodium glutamate-induced oxidative kidney damage and possible mechanisms: a mini review. *Journal of Biomedical Science*. 22: 93 – 98.
- Sharma A, Prasongwattana V, Cha'on U, Selmi C, Hipkaso W, Boonnate, P. (2013). Monosodium glutamate (MSG) consumption is associated with urolithiasis and urinary tract obstruction in rats. *PLoS One*. 8(9): 746 – 755.
- Slaoui M, Fiette, L. (2011). Histopathology procedures: From tissue sampling to histopathological evaluation. *Methods in Molecular Biology*. 691: 69 – 82.
- Uchendu CN, Isek T. (2008). Antifertility activity of aqueous ethanolic leaf extract of *Spondias mombin* (*Anacardiaceae*) in rats. *African Health Sciences Journal*. 8(3): 163 – 167.
- Wheatley JL. (2002). A gavage dosing apparatus with flexible catheter provides a less stressful gavage technique in the rat. *Laboratory Animals*. 31(7): 53 – 56.
- World Health Organization/United Nations Environment Programme (WHO/UNEP), Edited by Ake Bergman, Jerrold J, Heindel, Susan Jobling, Karen A, Kidd and R Thomas Zoeller (2013). *State of the Science of Endocrine Disrupting Chemicals - 2012*. An assessment of the state of the science of endocrine disruptors prepared by a group of experts for the United Nations Environment Programme and World Health Organization. An Inter-Organization Programme for the Sound Management of Chemicals. 1 – 289.