

Bilateral Ureteroneocystostomies After A Subtotal Hysterectomy: A Case Report And Review Of Literature

¹I.I. Okafor, ²S.C Ogbodo and ³C.O. Amu ⁴J.A. Ede

¹Departments of Obstetrics and Gynaecology, Enugu State University
College of Medicine, Enugu. E-mail: okaforii@yahoo.com

²Department of Surgery, College of Medicine, University of Nigeria, Enugu, Nigeria

³Department of Surgery, Enugu State University-College of Medicine. Enugu

***Author for Correspondence**

Abstract

Bilateral ureteral injuries are dreaded complications of any difficult pelvic surgery. The patient's data was summarized from the case note. Literature on the subject was reviewed and the results were compared with this case report. The patient had myomectomy in 2005 and life-threatening haemorrhage for recurrent uterine fibroid and adenomyosis in 2009. She had a difficult subtotal hysterectomy and left ureteroneocystostomy. In 2014, she had right ureteroneocystostomy for a 3-4cm stricture at the distal third of the right ureter. Both kidney functions were preserved. Careful surgery with a urologist is essential for prevention and management of ureteral injuries.

Keywords: Bilateral ureteroneocystostomies, Hysterectomy, Ureteral injuries.

INTRODUCTION

The close anatomic proximity of the ureters to internal genital organs predisposes them to injury during pelvic operations (Rut et al, 1991). The incidence of ureteral injury in obstetric and gynaecological operations ranges from 0.2-0.5% (Olayiwola et al, 2003), but can be as high as 30% in extensive pelvic surgery (Aghaji and Odoemene, 1999). Open gynaecological operations are still the leading cause of ureteral injuries in Nigeria and account for 87.8% in Enugu (Aghaji and Odoemene, 1999). The risk factors associated with ureteral injury during obstetric and gynaecological surgeries include an enlarged uterus greater than 12 weeks, previous pelvic surgery, ovarian neoplasms, endometriosis, pelvic adhesions, distorted pelvic anatomy, massive haemorrhage, and radiation therapy (Raut et al, 1991). Crushing, ligation, transection, kinking, avascular necrosis from ureteral stripping, electrocoagulation and resection of a segment are the common mechanisms of injury to the ureters. Transection and ligation were the reported common modes of injury to the ureters (Olayiwola et al, 2003; Oboro et al, 2002; Yousef et al, 2003).

Injury occurs in the lower third of the ureter in 51 %, upper third in 30% and middle third in 19% of cases. (Berkmen et al, 2003). The common sites of injury are lateral to the uterine vessels, the area of the ureterovesical junction close to the cardinal ligaments, the base of the infundibulopelvic ligament as the ureters cross the pelvic brim at the ovarian fossa and at the level of the uterosacral ligament. Unrecognised ureteral injuries are often associated with serious complications like increased hospital stay, reoperation, ureterovaginal fistula, hydronephrosis, sepsis, uremia, loss of kidney function, deterioration of quality of life and litigation (Viols 2000). Preventive measures like avoiding trauma to the ureters, quick recognition of the injury and prompt treatment are essential in prevention of these complications. We report our case of bilateral ureteroneocystostomies in a nulliparous woman who had a difficult subtotal hysterectomy.

Case Report

Mrs. N.I. was a 34-year old nulliparous thteacher who presented on 27 February 2009 with a 12-year history of infertility, severe

menstrual pain, excessive menstrual bleeding and painful coitus. She had myomectomy in a private hospital in 2005. Her ultrasound report showed adenomyosis coexisting with a large left endometriotic cyst. There was a 14-week, tender, firm and very immobile supra-pubic mass. She was informed of a possible difficult repeat surgery and was managed conservatively with haematinics and analgesics. On 4th June 2009, she was admitted to the gynaecological ward as an emergency for profuse vaginal bleeding and a packed cell volume of 19%. She had 4 pints of blood transfused and was booked for hysterectomy and excision left adnexal cyst with a urologist on 8/6/2009. The operative findings were massive adhesion of the uterus to the peritoneum, small and large intestines; intra-peritoneal blood clot of about 500mls, the ovaries were matted with the fallopian tubes especially on the left side and blood stained urine. The estimated blood loss was 1.5 Litres.

On the first postoperative day, the abdominal wound dressing was soaked with fluid and the abdominal drain drained 200mls of clear urine. She was booked for a second operation. On 12/6/2009 left ureteroneocystostomy (figures 1 and 2) was done for partial transection of about 1.0 cm on the distal third of left ureter. The right ureter was

Procedures

The procedure undertaken was approved by the hospital Ethical Committee and there were no conflict of interest.

Under general anaesthesia and in supine position, routine cleaning and draping was done. Via the previous sub umbilical midline incision access was gained to the pelvis. The right ureter was localised and dissected out at the point of crossing the right external iliac vessels. Ten 10mls of sterile methylene blue dye was injected into the ureter. There was no intra-abdominal Extravasation of the dye, but the urine in urethral catheter turned blue. A repeat of the procedure on the left side showed intra-abdominal extravasation of the methylene blue dye at the site of damage. Intra-venous injection of 80mg of frusemide also showed the site of injury by spurts of urine in the lower third of the left ureter. The urinary bladder was mobilised and left - ureteroneocystostomy effected using vicryl 3-0 suture and without tension. The ureter was tunnelled below the bladder mucosa to prevent reflux of urine into the neoureter. A stent was passed into the neoureter and brought out separately through the anterior abdominal wall. The bladder wound was closed in two layers. An

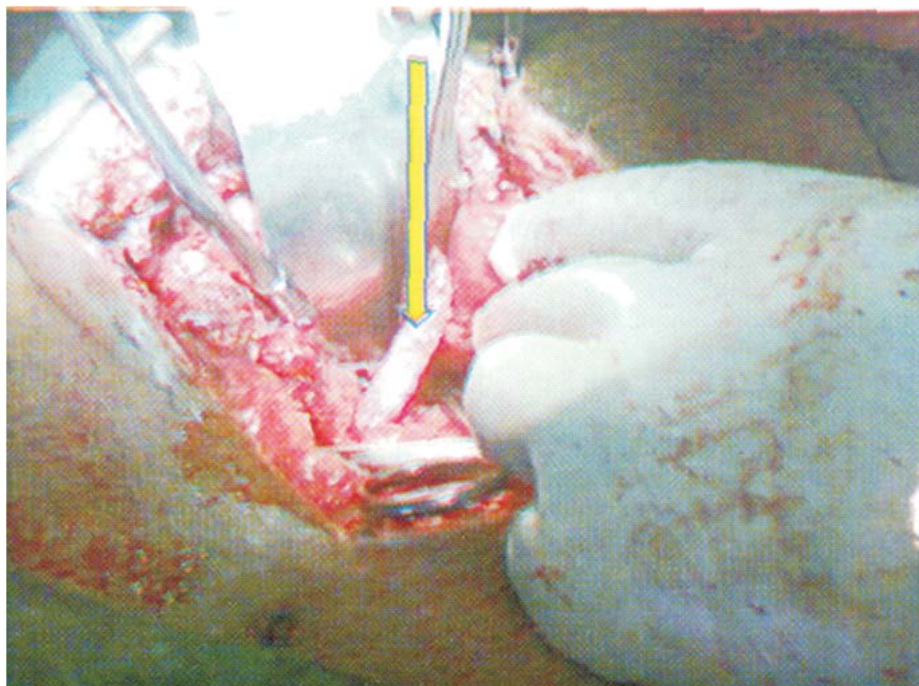


Figure 1: Mobilized left ureter being implanted into the bladder (see arrow above)

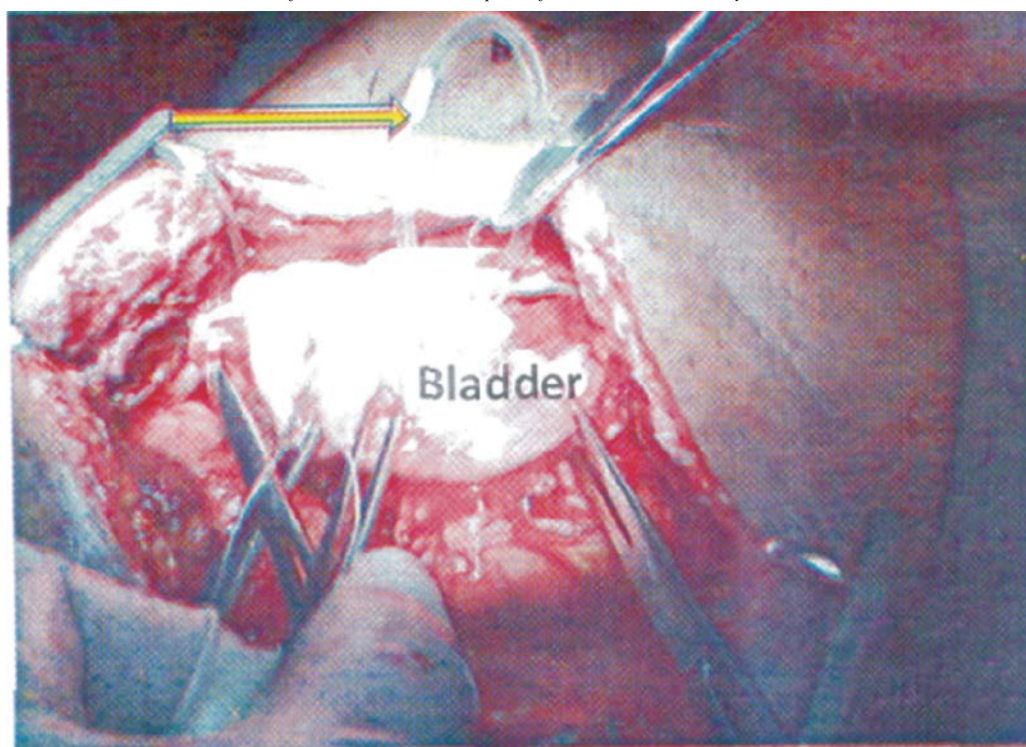


Figure 2: Stent from the skin to the neoureter for separate drainage. See arrow above.

abdominal drain was left in-situ and mass closure of the anterior abdominal wall done with nylo-2 to fascia and skin. Her immediate post operative condition was satisfactory.

Post operative follow up was uneventful. The left ureteral stent was draining adequate clear urine. On 3rd postoperative day the abdominal drain was removed and postoperative packed cell volume was 30%. The stent and urethral drains-were removed 14th and 17th post operative days respectively. She was discharged on 18th postoperative day. She was seen a month later in our gynaecological clinic in a healthy condition. The histology reports confirmed adenomyosis, normal fallopian tube and ovarian tissue. Her renal scan showed normal kidneys. She was ordered to do intravenous urography (IVU) after three months and then every six months for three years.

Subsequent follow up She was in good health but could not do the ordered IVU because of financial difficulty. In 2013, she had recurrent right acute pyelonephritis and was managed with antibiotics, The IVU done in April 2014 revealed right hydroureter and hydronephrosis in the previously normal right ureter. An impression of distal right ischaemic ureteric stricture was made and she was worked up for

another exploration. The operative findings included a long (3--km) segment stricture at the distal third of the right ureter, grossly dilated ureter proximal to the strictured ureter, hydronephrotic right kidney. The ureteroneocystostomy on the left was intact. The right ureter was mobilized and transected from the strictured segment. A ureteroneocystostomy was effected as was previously done on the left. She was discharged after two weeks. The post operative follow up was uneventful.

DISCUSSION

Ureteral, injury in obstetric and gynaecological operations is a serious complication that is dreaded by many obstetricians and gynaecologist because of the associated severe morbidity and even mortality (Oboro et al, 2002; Swati et al, 2004). This fear informed our initial conservative care and the involvement of a urologist as soon as surgery was inevitable because of the life-threatening haemorrhage in Mrs N.1. The risk factors to ureteral injury in our patient include an immobile uterus of 14 weeks size, previous pelvic surgery with pelvic adhesion, adenomyosis and large left endometriotic cyst as were identified by other workers (Raut et al,

1991; Harkki-Siren et al, 1998). Abdominal hysterectomy is a common cause of ureteral injury as in this patient (Olayiwola et al, 2003; Obora et al, 2002). Post operative ischaemic ureteric necrosis can also cause ureteral injury as reported in our patient. Ureteral transection and ligation were the reported common modes of injury to the ureters (Olayiwola et al, 2003; Oboro et al, 2002). The lower third of the left ureter was also the commonest site of injury as in our patient (Bcrkrnen et al, 2000; Harkki-Silen et al, 1998). Mrs N 1. had about 1cm transection of the lower third of the left ureter with 50% of the diameter involved and in 2014 ischemic necrosis of 3- 4cm segment of the distal third of the right of the right ureter.

Injury to ureter is a venial sin and must not be followed by the mortal sin of failure to recognize the damage (Higgins, 1967). About 70% cases of ureteral injury present in the postoperative period with urine in abdominal drain and soaking of wound dressing with fluid as in Mrs N. 1. (Wann et al, 1988). Injection of sterile methylene blue into the left ureter confirmed our diagnosis of left ureteral injury. Other modes of presentation of injury to ureter include flank pain, fever, haematuria, peritonitis, urinoma, anuria and secondary hypertension.

Our high index of suspicion prompted our diagnosis of right ureteral injury in this patient when she presented with recurrent right pyelonephritis. Diagnosis of ureteral injury can be confirmed with intravenous urogram, retrograde ureterogram, cystoscopy, three swab test (Randawa et al, 2009), and other contrast-dye tests. Intraoperative intra-venous injection of 5mls of indigo carmine is an accurate intraoperative means of diagnosis of ureteral injury that was not used in this patient (Stanhope et al, 1991). Ureteral dissection and avoidance of traumatisation is another preventive strategy we failed to utilise in this patient (Newman et al, 1991). Renal ultrasound can show hydronephrosis and retroperitoneal urinomas when there is ureteral damage. The essence of involving a urologist early in this patient management was to prevent iatrogenic injury to the ureters (Wann et al, 1988).

The management of ureteral injury depends on the time of diagnosis, aetiology, length and

location of damage and the patient's condition. The general principles of care (Utrie, 1988) include: tension-free anastomosis after adequate mobilisation, preservation of the blood supply to the ureter during its mobilisation, use of fine absorbable sutures to maintain watertight anastomosis, putting stent in neoureter with separate drain and drainage of site of anastomosis to avoid accumulation of urine.

These principles were applied during the bilateral uteroneocystostomies in our patient.

Sepsis, unstable patient, haematoma and abscess formations are contraindications to immediate ureteral repair (Swati et al, 2004). Percutaneous nephrostomy drainage can be done until the patient is fit for ureteral repair. The options for management of ureteral injury depend on location of damage. Ureterourterostomy, transureteroureterostomy, ileal interposition and renal autotransplantation can be done for proximal third ureteral injuries. For middle third of the ureteral injuries urcteroureterostomy, Boari flap and transureteroureterostomy are treatment options. Ureteroureterostomy, ureteroneocystostomy and Psoas hitch are treatment options for distal third ureteral injuries. The complications associated with ureteral repair include stricture, infection, haematoma and ureteral reflux. The left urteroneocystostomy was intact in Mrs. N 1.

CONCLUSION

Bilateral ureteral injury is rare. High index of suspicion is essential to avoid missing ureteral injuries and the associated serious morbidity in delayed presentations. Efforts should be made to make intraoperative diagnosis with a urologist if ureteral injury is suspected. The outcome of the urteral injury repair is general good if the principles of ureteric surgery are followed.

REFERENCES

- Aghaj i, A. E. and Odoemene, C. Ureteric injuries in Enugu, Nigeria. *East Afr. Med. J.* 1999; 76: 184-188.
- Berkmen F, Peker A.E, Alagol H, Ayyildiz A, Arik AI, Basay S. Treatment of iatrogenic ureteral injuries during various operations for malignant conditions. *J Exp Clin Cancers Res* 2000; 19:441-445
- Harkki-Siren P, Sjoberg J, Titinen A. Urinary tract injuries after hysterectomy. *Obstet Gynecol.* 1998;92: 113-118.

- Higgins CC. Ureteral injury during surgery. A review of 87 cases. *JAMA* 1967; 199:82-88.
- Mann WJ, Arato M, Patsner B, Stone MI. Ureteral injuries in an obstetrics and gynaecology training program: aetiology and management. *Obstet Gynecol*. 1988; 72:82-85.
- Neuman M, Eidlman A, Langer R, Golan A, Bukovsky I, Caspi E. Iatrogenic injuries to the ureter during gynecologic and obstetric operations. *Surg Gynecol Obstet* 1991; 173: 268-272.
- Oboro V. O, Dare F. O., Fadiora S. O, Aderounmu A. O. A., Adeoti M. L., and Ajadi A. M. Ureteric Injuries Following Pelvic Operations. *East African Medical Journal* Vol. 79 No. II November 2002.
- Olayiwola B, Shittu, Olusoji. A. Adeyanju, Adekola S, Adebayo, Abiola Okunlola, Oladapo O, Olayemi, Kolawole A, Obisesan. Ureteric injuries from Obstetric and Gynaecological operations at University College Hospital Ibadan: a 20-year review. *Trop J Obstet Gynaecol* 2003, 20:32-36.
- Randawa AJ, Khalid L, Abbas A. Diagnosis and Management of urterovaginal fistula in a Resource-Constrained Setting: Experience at a Distric Hospital in Northern Nigeria. *Libyan J Med*. 2009; 4:45-48. AOP:081-101.
- Rut V, Shrivastava A, Nandanwar S, Bhattacharya M. Urological injuries during obstetric and gynaecological surgical procedures. *J Postgrad Med* 1991; 37:21
- Stanhope CR, Wilson TO, Utz WJ, Smith LH, O'Brien PC. Suture entrapment and secondary ureteral obstruction. *Am J Obstet Gynecol* 1991; 164: 1513-1517.
- Swati Jha, Aravinthan (Arri) Coomarasamy, Kiong Kong Chan Ureteric injury in obstetric and gynaecological surgery. *The Obstetrician and Gynaecologist* 2004; 6:203-208.
- Utrie JW Jr. Badder and ureteral injury: prevention and management. *Clin Obstet Gynecol* 1988; 41: 755-763.
- Viols GA. Litigation of laparoscopic major vessel injuries in Canada. *J Am Assoc Gynecol Laparosc* 2000; 7: 503-509.
- Yousef S, Matani, Kamal E, Bani-Hani, Ibrahim H, Bani-Hani. Ureteric injuries during obstetric and gynaecologic procedures. *Saudi Med J* 2003; Vol. 24 (4):365-368.